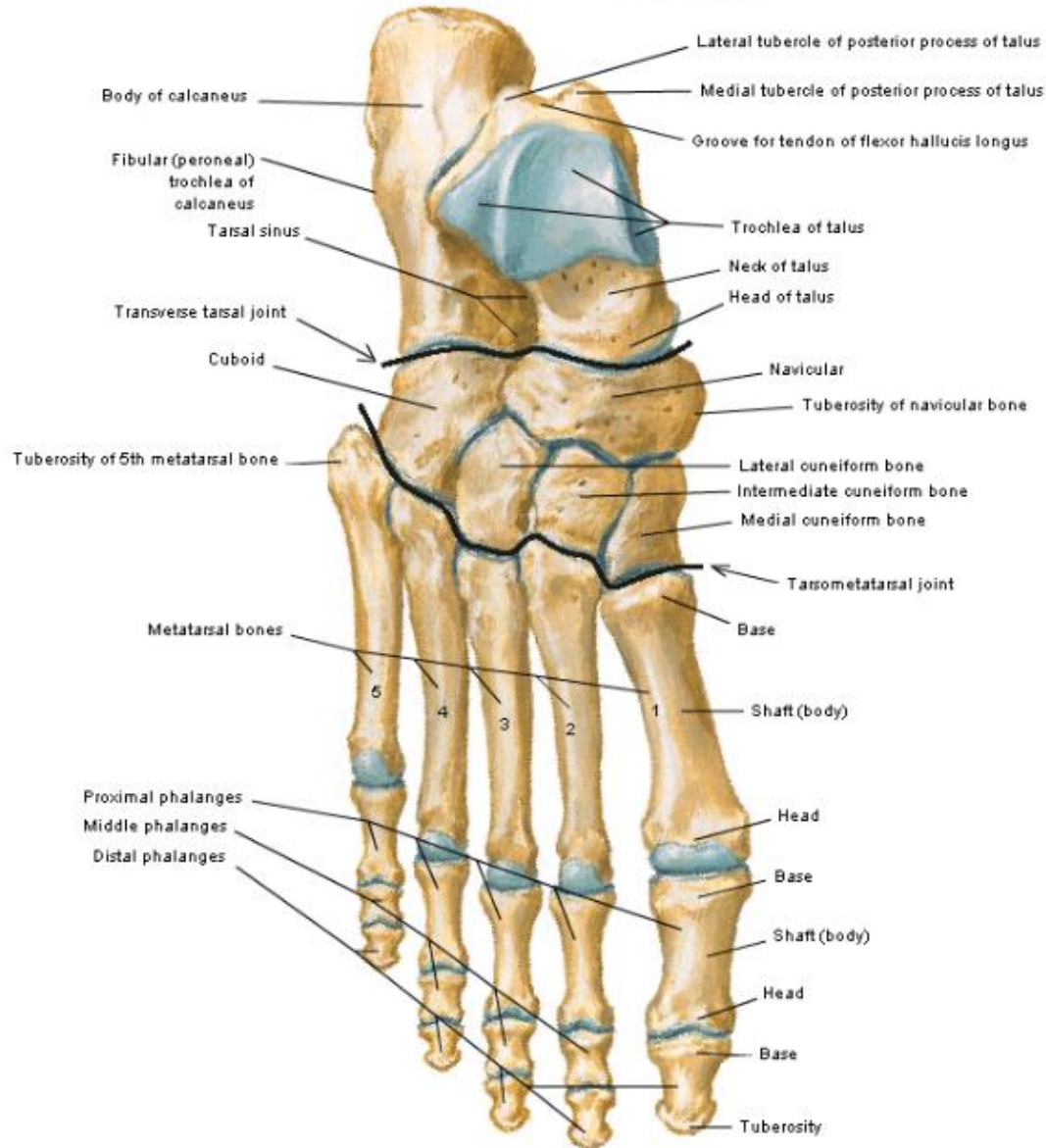


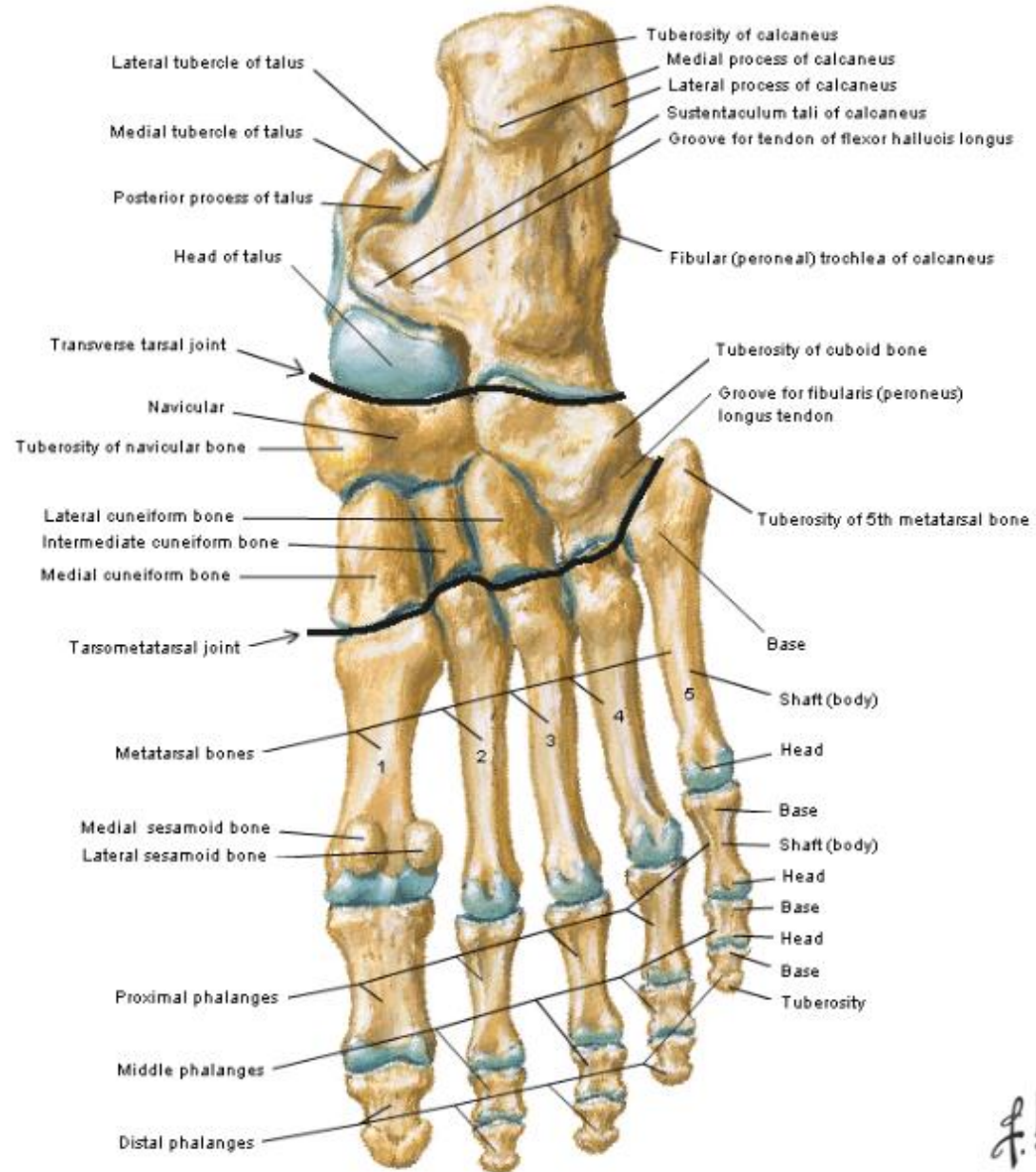
Bones Of Foot

Bones of Foot Dorsal View



F. Netter M.D.
© H&N

Bones of Foot Plantar View

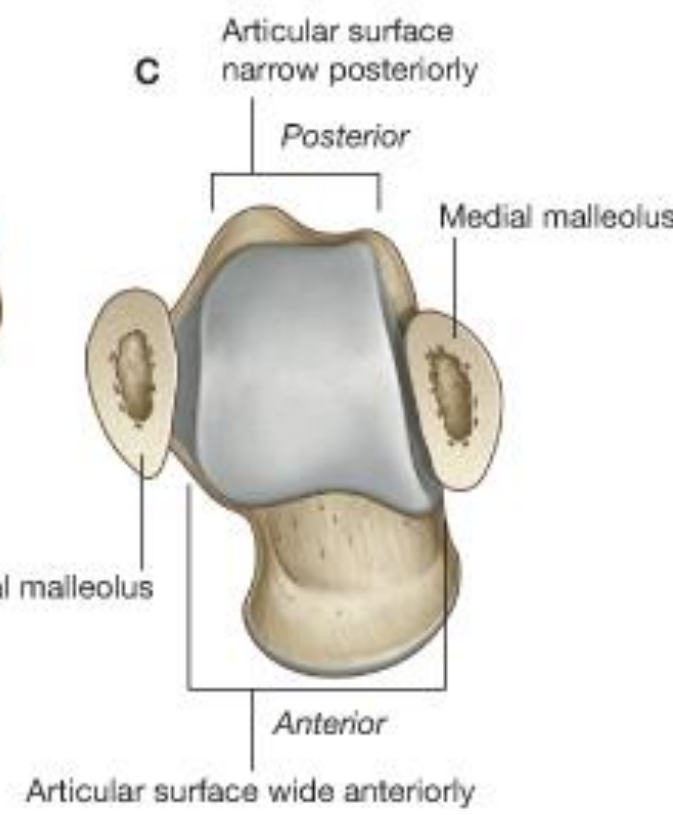
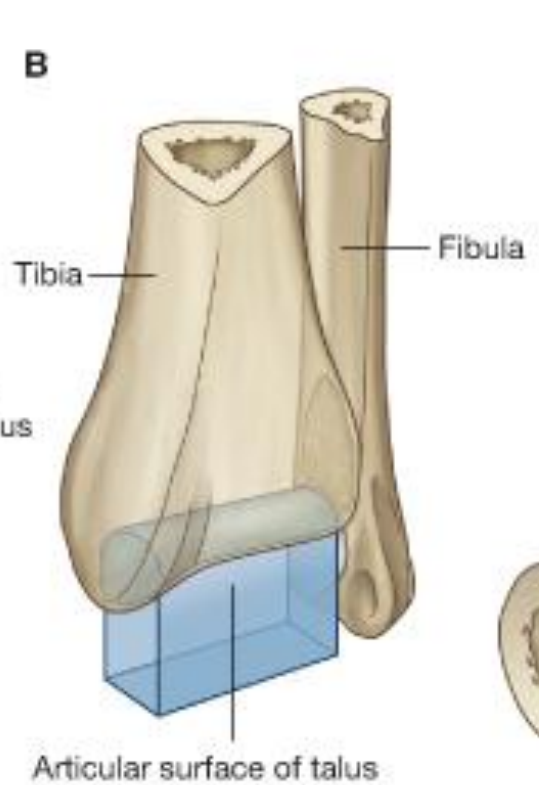
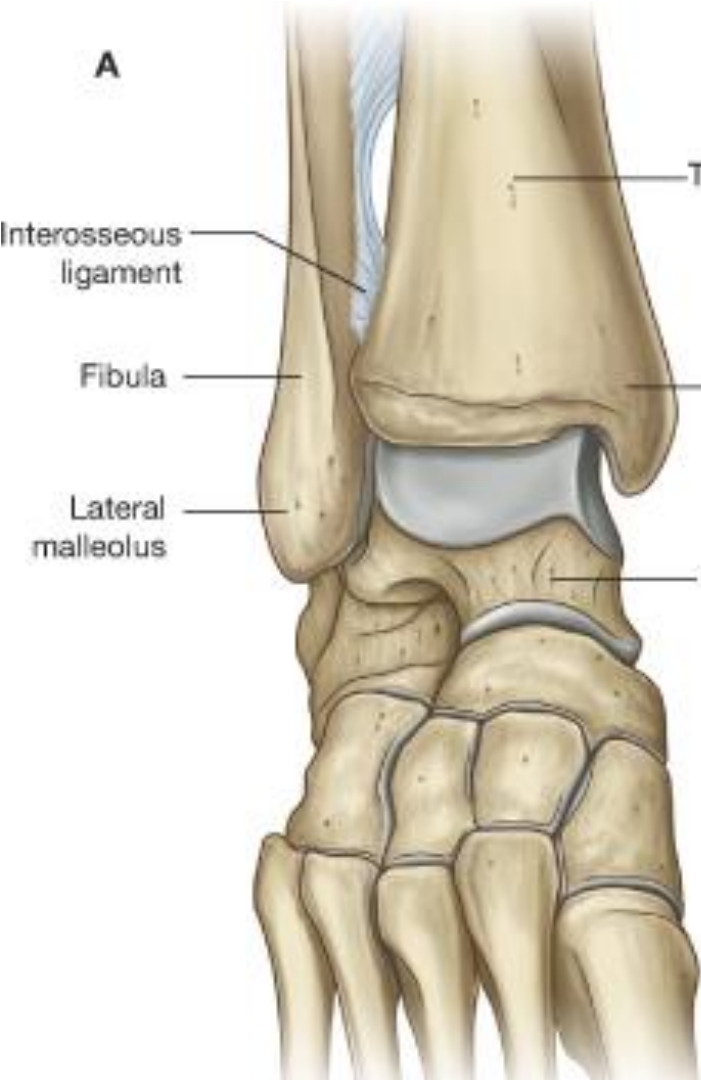


Joints

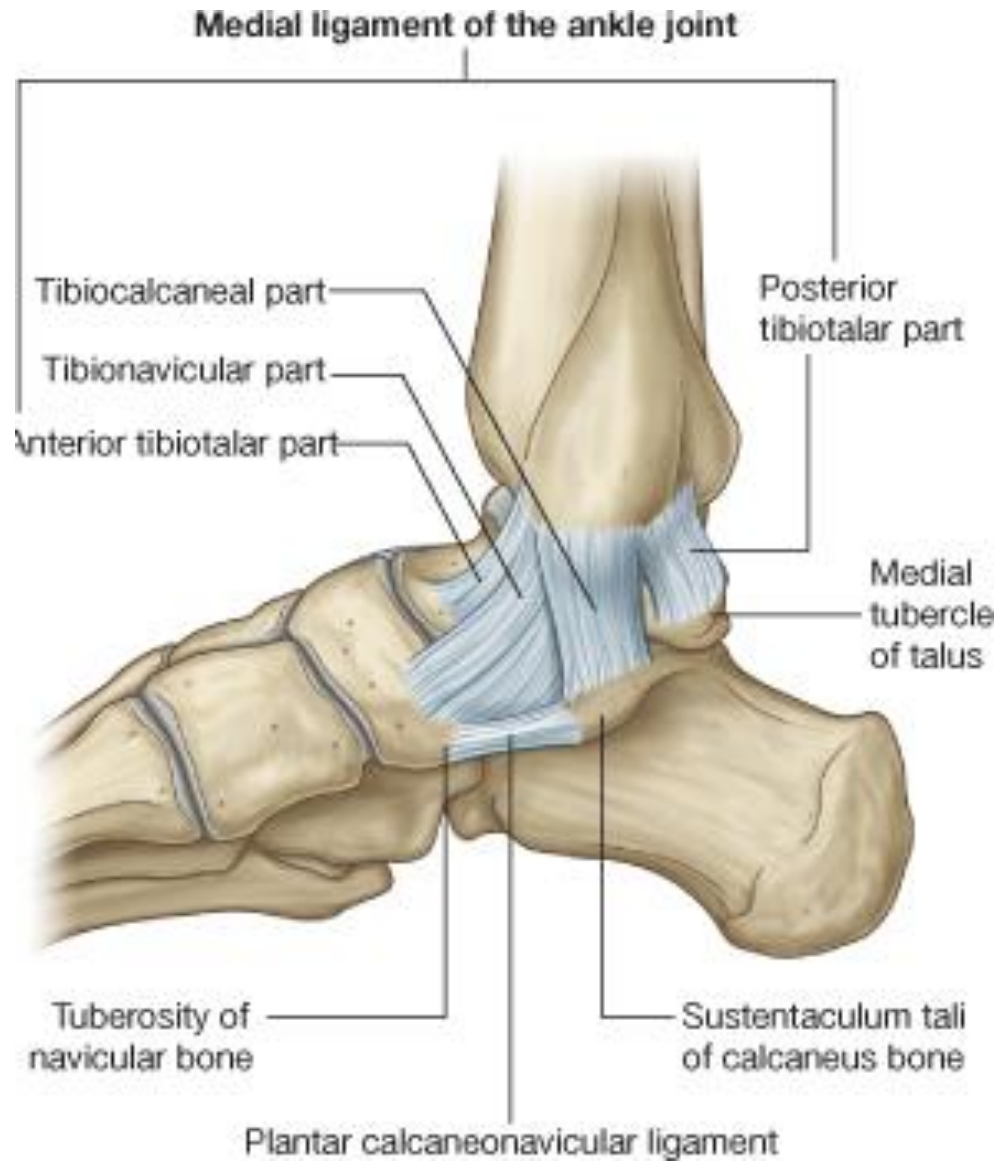
Ankle Joint

(Taloacrural Joint)

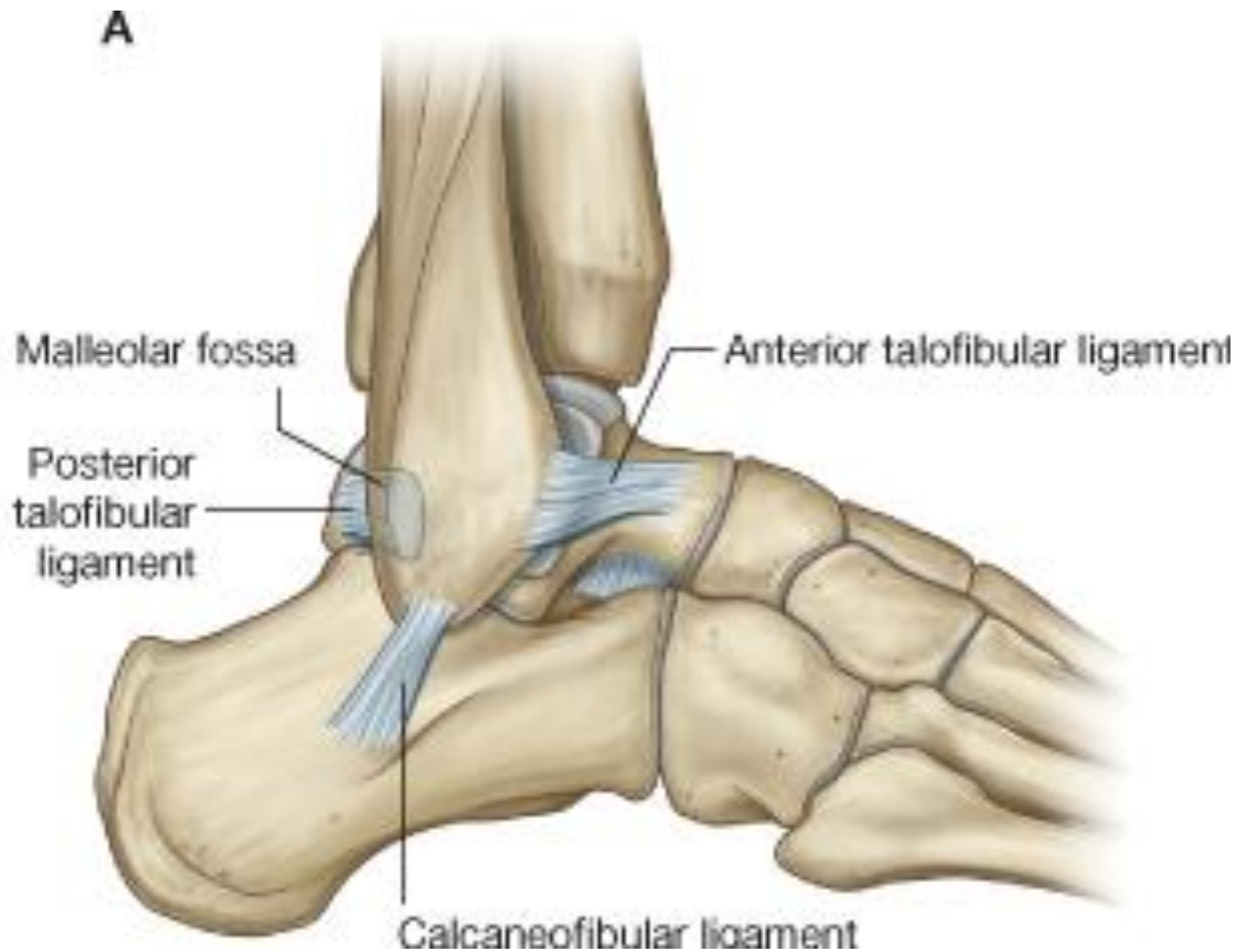Hinge Type Synovial Joint



Medial Ligaments (Deltoid)



Lateral Ligaments



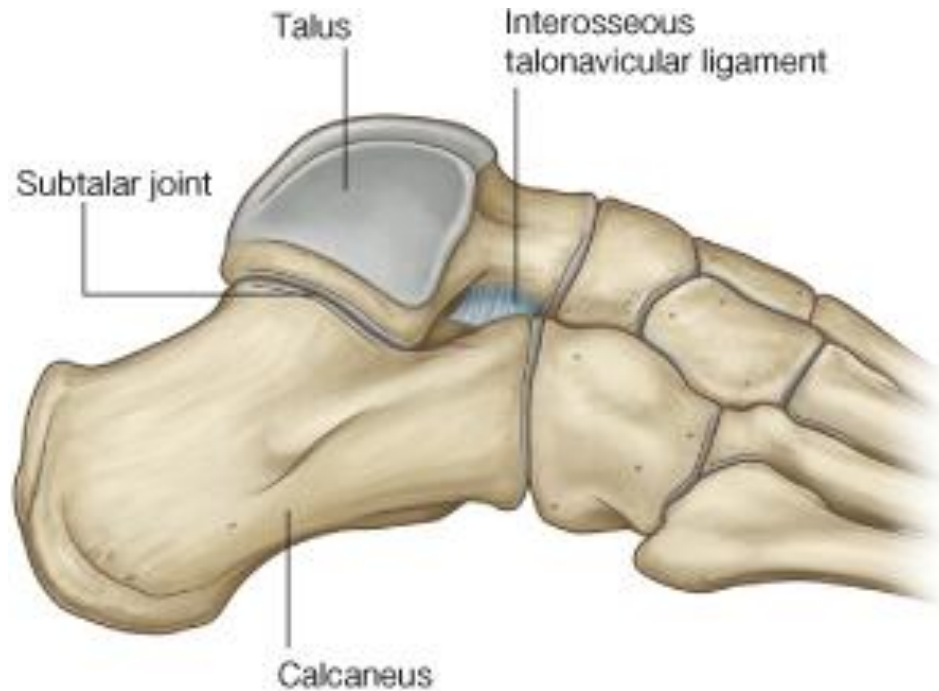
Movements

- Dorsiflexion
- Planterflexion

Other Joints

Subtalar Joint / Talo-calcaneal

- Plane Synovial
- Inversion / Eversion



Calcaneocuboid part
(Saddle Joint)

Talonavicular Part
(Plane Synovial)

Talocalcaneonavicular Part
(Ball & Socket Joint)

(Plane Synovial)

(Ellipsoid/ Condyloid)

(Hinge)

